





Available online at
 ScienceDirect
www.sciencedirect.com

Elsevier Masson France
 EM|consulte
www.em-consulte.com



ORIGINAL ARTICLE

Posterior approach and dislocation rate: A 213 total hip replacements case-control study comparing the dual mobility cup with a conventional 28-mm metal head/polyethylene prosthesis

R. Bouchet, N. Mercier, D. Saragaglia*

Orthopaedic Surgery and Sports Traumatology Academic Clinic, Grenoble Teaching Medical Center, South Hospital, 38130 Échirolles, France

Accepted: 27 July 2010

KEYWORDS

Dislocation;
Total hip prosthesis;
Dual mobility cup;
Posterior approach

Summary

Introduction: Dislocation is a frequent complication of total hip arthroplasties (THA) especially in older patients, especially when using a posterior approach. In these cases, dual mobility (DM) cups developed by Gilles Bousquet in 1975 can be indicated to reduce this complication risk.

Hypothesis: Dual mobility cups reduce the rate of dislocation in primary total hip arthroplasty using posterior approach in a single-surgeon series.

Aim: Test this hypothesis in a controlled study to compare the rate of dislocation in primary total hip arthroplasties done in patients over 50 years old either with a dual mobility cup or a conventional metal-on-polyethylene 28-mm diameter head.

Patients and methods: Two consecutive series of primary total hip replacements were performed by a single surgeon using a posterolateral approach. The piriformis tendon was left intact. The DM series included 105 patients who underwent arthroplasty between January 2005 and June 2007 with a dual mobility cup (60 women and 45 men, mean age 76.6 ± 5.65 years old [53–93]). The control series (S series) included 108 patients who underwent arthroplasty (56 women and 52 men, mean age 74.2 ± 5.9 years old [53–87]) with a conventional 28-mm polyethylene cup between January 2003 and June 2005. All hip replacements included a 28-mm metal-polyethylene cup and a 12–14-mm Morse taper. Both groups were comparable for gender, diagnosis, body mass index, type of anesthesia and ASA score distribution. All patients included in this series had a minimum follow-up of 1 year.

* Corresponding author. Tel.: +33 4 76 76 58 33; fax: +33 4 76 76 58 18.
E-mail address: DSaragaglia@chu-grenoble.fr (D. Saragaglia).

Results: There were no dislocations in the DM series and five early dislocations (before the third month) in the S series for a rate of 4.63%. Although the rate of dislocation was higher in the S series (4.63% vs 0%), the difference was barely significant ($P=0.0597$).

Discussion: This study comparing the incidence of dislocations after THA with conventional or dual mobility cups, shows that even using a posterior approach and in older patients, dual mobility cups increase stability with no postoperative dislocations. Although results are barely significant, a larger series should confirm the benefit of this implant. In this series, morbidity was not increased with dual mobility cups.

Level of evidence: Level III: retrospective case-control study.

© 2010 Elsevier Masson SAS. All rights reserved.

Introduction

Dislocation is a frequent complication of total hip arthroplasties (THA) and is considered the second cause of THA failure after loosening [1]. Today patients have difficulty tolerating or accepting this complication, which used to be considered inevitable. The rate of dislocation, which may be underestimated, varies in the literature between 0.16 [2] and 9.5% [3] while one US series [4] of 58,521 hip replacements reported a rate of 3.9% in the six postoperative months. Moreover, the frequency of dislocations tends to increase with follow-up and some authors report rates of 22% after 1 year [5], 26% after 2 years [6] and 32% after 5 years [7].

Since 2005, we have chosen to use implants with large diameter heads to reduce the rate of dislocation, that is head components whose size are similar to that of the anatomical/native femoral head. Thus, in young patients with a life expectancy of more than 20 years, we use metal-on-metal cups with a large head diameter, and in patients older than 70, we use dual mobility cups, which we also consider to be large head components.

In the 1970s, Gilles Bousquet developed the dual mobility cup (Fig. 1) to reduce the incidence of dislocation. The idea was to associate the benefits of two different systems: obtain maximum stability by implanting a large head

component, based on the theory of Mac Kee and Farrar [8] and reduce wear with a polyethylene insert based on Sir John Charnley's principle of "low-friction arthroplasty" [9]. The dual mobility cup associates two concentric articulations: a large diameter between the mobile polyethylene liner and the metal cup, and another small retentive diameter between the head and the liner.

The aim of this study was to compare the rate of dislocations following THA using conventional or dual mobility cups in patients whose mean age was 75 years old, in a case-control single-surgeon series.

Patients and methods

Patients

This is a retrospective study of medical files, with a minimum follow-up of 1 year, of unselected patients who were consecutively included based on their age. The inclusion criteria were patients older than 50, who required primary THA. Exclusion criteria were revision THA and patients younger than 50 with an indication of hard-on-hard bearings.

Dual mobility series (DM series)

The dual mobility series included 105 patients who underwent surgery by the same surgeon (DS) between January



Figure 1 Dual mobility cementless press-fit cup (Novae Sunfit™, Serf, Décines, France).

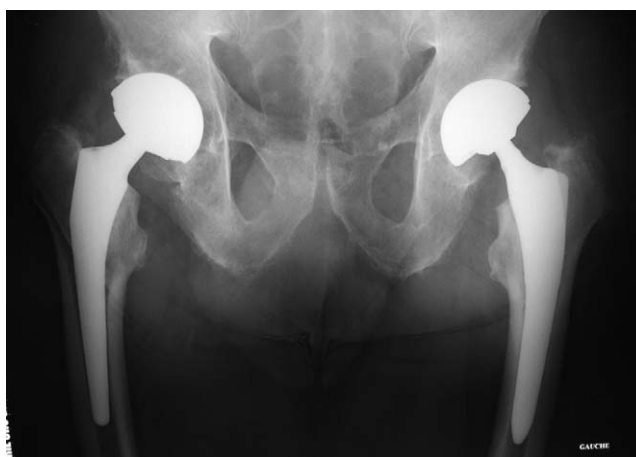

Figure 2 Bilateral arthroplasty with a dual mobility press-fit cup: on the right, stem with Morse taper 12–14; to the left, stem with Morse taper 8–10 (not part of this series).

Table 1 Comparative outcomes in the two series.

	Dual mobility series (DM) (n = 105)	Conventional series (simple) (S) (n = 108)	Significance
Age (years)	76.6 ± 5.65	74.2 ± 5.9	P = 0.0026
Gender (M/F)	45/60	52/56	NS
BMI (kg/m ²)	27.1 ± 2.46	26.9 ± 2.34	NS
Etiology	95 osteoarthritis (90.5%) Other etiologies (9.5%)	100 osteoarthritis (92.6%) Other etiologies (7.4%)	NS
Stem type	61 PFL 42 PFS 2 others 30 cementless (28.6%)	69 PFL 39 PFS 0 others 34 cementless (31.5%)	NS
Type of anesthesia	54 general anesthetics (51.4%) 51 spinal anesthetics (48.6%)	56 general anesthetics (51.9%) 52 spinal anesthetics (48.1%)	NS NS
ASA score	ASA 1: 37 (35.2%) ASA 2: 47 (44.8%) ASA 3: 21 (20%)	ASA 1: 37 (34.3%) ASA 2: 50 (46.3%) ASA 3: 21 (19.4%)	NS
Dislocations	0	5 (4.63%)	P = 0.0597

BMI: body mass index, M: male F: female, PFS: PFTM standard stem, PFL: PFTM lateral stem (Zimmer, Etupes, France), ASA: American Society Anesthesiologists.

2005 and June 2007 for THA with a dual mobility cup (Fig. 2) and a 28-mm diameter head. Patients included 45 men and 60 women, mean age: 76.6 ± 5.65 (53–93), mean body mass index (BMI): 27.1 ± 2.46 kg/m² (22–34) (Table 1). The indication for THA was primary osteoarthritis of the hip in 95 cases (90.5%), avascular necrosis of the femoral head in three patients (2.85%), four traumatic sequelae (3.8%) (two cases of femoral malunion following internal fixation, one case of sequelae following a femoral neck fracture, one case of osteoarthritis secondary to acetabular fracture), one case of rheumatoid arthritis (0.95%), one case of sequela from a congenital dislocation (0.95%) and one case of Legg-Calve-Perthes disease (0.95%). General anesthesia was used in 54 cases (51.4%) and spinal anesthesia in 51 cases (48.6%). Patient distribution according to the ASA score (American Society of Anesthesiologists) [10] was: 37 patients ASA 1 (35.2%), 47 ASA 2 (44.8%) and 21 ASA 3 (20%) (Table 1).

We used 61 PFTM lateral stems (58.1%) (Zimmer, Etupes, France), 42 PFTM standard stems (40%) (Zimmer, Etupes, France), one OmnicaseTM (0.95%) (Zimmer, Etupes, France), one AvenirTM lateral stem (0.95%) (Zimmer, Etupes, France) (Table 1). The amount of lateralization of the stem was determined during preoperative planning to restore the morphology of the patient's hip as well as possible, in particular femoral offset [11]. Fixation of 30 stems was cementless; in these cases the stems were coated with hydroxyapatite (28.6%) and 75 were cemented (71.4%) (Table 1). All these stems had a 12–14-mm Morse taper with no particular narrowing of the neck. All cups were cementless including, 94 NovaeTM cups (89.5%) (Serf, Décines, France), five StaffitTM cups (4.8%) (Zimmer, Etupes, France), five AvantageTM cups (4.8%) (Biomet, Valence, France) and one GyrosTM cup (1%) (Depuy, Saint Priest, France). All the cups were impacted by press-fit without additional fixation with pins or screws. The mean follow-up was 28 ± 8.1 months (range 14–43).

Conventional cup series (S series)

The conventional cup series included 108 patients, operated by the same surgeon (D.S.), between January 2003 and June 2005, for primary THA with a conventional (simple mobility) metal-on-polyethylene cup and a 28 mm head component. There were 52 men and 56 women, mean age: 74.2 ± 5.90 years old (53–87), mean BMI: 26.9 ± 2.34 kg/m² (21–33) (Table 1). The indication for THA was primary osteoarthritis of the hip in 100 cases (92.6%), avascular necrosis of the femoral head in eight patients (7.4%). General anesthesia was used in 56 patients (51.9%) and spinal anesthesia in 52 patients (48.1%) (Table 1). Distribution of patients by ASA score was: 37 patients ASA 1 (34.3%), 50 patients ASA 2 (46.3%) and 21 patients ASA 3 (19.4%) (Table 1).

There were 69 PFTM lateral femoral stems (63.9%) (Zimmer, Etupes, France), 39 PFTM standard stems (36.1%) (Zimmer, Etupes, France) including 34 cementless (31.5%) and 74 cemented (68.5%) stems, so that the distribution of the type of stems and fixation were comparable to the DM series with the same taper (Table 1). Forty-four cementless St NaborTM cups were implanted (40.7%) (Zimmer, Etupes, France), 41 cementless CédiorTM cups (38%) (Zimmer, Etupes, France) and 23 cemented cups (21.3%). The latter cups were implanted in the oldest patients in the series. The polyethylene was flat-edged and we did not use any antidislocation elevated rims. The mean final follow-up was 52 ± 8 months (38–67).

Methods

Surgical method

Patients in both series were operated by a reduced Moore posterolateral approach, which left the piriform tendon intact. The articular capsule was sutured at the end of surgery, without closing the other pelvirochanteric

muscles. The surgical technique was exactly the same in all patients, with a goal of obtaining 40° of cup inclination and 15° of anteversion as well as of controlling any impingement between the neck component and the cup, which could result in dislocation during 45° internal rotation and 90° flexion. Both groups of patients were given the same advice on movements to be avoided to prevent dislocation.

Statistical methods

All of the results were collected and analysed using Statview™ (SAS, Cary, NC, USA) software. Comparison of the rate of dislocation was performed with the Fischer Test. The other variables were analysed with the Chi² test. The level of significance was set at 5%.

Results

Comparison of two groups

The patients in the DM group were significantly older than in the S series. However, there was no significant difference between the two groups for the distribution of gender, the body mass index (BMI), the type of anesthesia, patient distribution by ASA score, or the etiology for the indication of THA. Moreover, there was no significant difference between the two groups for the type of femoral component used or the type of stem fixation (Table 1).

Rate of dislocation

There were no cases of dislocation in the DM series, while five out of 108 patients in the S series (4.63%) presented with at least one episode of dislocation after surgery. All dislocations were posterior. They all occurred in cases of primary osteoarthritis of the hip. None of the patients had neurological sequelae such as hemiplegia, polio, or Parkinson's disease, while the ASA score in these patients were the following: one patient had an ASA score of 1, three patients had an ASA of 2 and one patient had an ASA of 3. Thus these were not high risk hips. On the other hand, in the first case of dislocation, the patient's contralateral leg was amputated and there was a prosthetic limb.

Case 1

A 74-year-old man who received a standard PF™ cemented implant with a St Nabor™ cup presented with dislocation on D+35, which occurred as he was putting on his socks. His contralateral limb was amputated and he had a leg prosthesis. Cup inclination on standard X-ray was 40°. He was treated by simple reduction under short general anesthesia with no further recurrence at the last follow-up of 5 years and 3 months.

Case 2

A 76-year-old woman with a PF™ lateral cemented replacement, a Cédior™ cup, with an inclination of 45° on standard X-ray, presented with dislocation on D+35 which occurred while she was seated on a stool to bathe. This dislocation was treated with simple reduction, with no recurrence at follow-up of 3 years and 2 months.

Case 3

A 75-year-old man with a PF™ lateral cementless stem and a Cédior™ cup, with 45° inclination on standard X-ray, presented with dislocation on D+26 which occurred as he was sitting down on a low chair. Dislocation was reduced under general anesthesia, with recurrent dislocation on D+30; during the first reduction, the cementless component had turned in the diaphysis causing a Merckel fracture and (impaction) of the stem modifying implant anteversion. The patient underwent revision surgery with a lateral cemented PF™ stem and a Novae™ cup. The final result at 3 years and 1 month of follow-up was satisfying.

Case 4

A 78-year-old man with a lateral cementless PF™ implant and a Cédior™ cup, with an inclination of 40° on standard X-ray, presented with dislocation on D+54, which occurred while he was exercising. The dislocation was treated by simple reduction, without recurrence at 3 years and 4 months of follow-up.

Case 5

Dislocation occurred in a 70-year-old man 2 months and 8 days after surgery. The hip replacement included a standard PF™ cemented stem and a St Nabor™ cup with an inclination of 50° on standard X-ray. Dislocation was treated with simple reduction, without recurrence at 4 years of follow-up

Thus five patients presented with at least one dislocation. There was no recurrence in four of them. Only one case of recurrence occurred, but this was due to migration of a cementless stem.

All dislocations occurred within 3 months after surgery (Table 1). Three dislocations occurred with a Cédior™ cup and two with a St Nabor™ cup. In three cases, the femoral component was a lateral PF™ and in two cases a standard PF™ with a cemented stem in three cases and a cementless stem in two. Thus the dislocations did not occur with one particular type of implant. Although the rate of dislocations was higher in the S series (4.63% vs 0%), there is no significant difference between the incidence of dislocations following THA with a conventional and a dual mobility cup; *P* was barely significant (*P* = 0.0597) (exact Fischer's test *F*).

Discussion

The aim of this study was to compare the incidence of dislocations following THA using dual mobility and conventional (simple mobility) cups in patients older than 50, operated by a single experienced surgeon under the same technical conditions. No dislocations occurred in the DM group, thus confirming the stability of dual mobility cups. Nevertheless, there was no significant difference between the incidence of dislocations using conventional and dual mobility cups, because the results were barely significant (*P* = 0.0597). The statistical power of this comparison is certainly limited by the small size of the patient samples, and the few number of events. The low frequency of this complication is comparable to the results in the literature [12,13].

We began using the dual mobility system in 2005 in older patients at risk of instability, to reduce the incidence of dis-

location. Indeed, implants with a dual mobility component and their "large head effect" improve stability of the arthroplasty [14]. Implant instability can occur as a result of two distinct mechanisms; deoaptation and impingement (CAM-effect). Thus, the smaller the head, the earlier impingement can develop and the greater the risk of impingement [1]. Impingement also depends upon the diameter of the neck component [1]. Thus, for the same implant components, the risk of dislocation is greater with a small diameter head and a large diameter neck [1].

Moreover, the results of wear and implant survival with dual mobility cups are good compared to "conventional" metal-polyethylene bearing cups. Lautridou et al. [12] showed an implant survival rate at 15 years of 85.2%. Aubriot et al. [15] had a 5-year survival rate of 97% while in the series by Farizon et al. [16], the survival was 95.4% at 10 years. Recently Phillipot et al. [13] found that implant survival at 15 years was 96.3%. Thus the dual mobility cup did not cause excess polyethylene wear, as shown by Adam et al. [17] in an analysis of 40 explanted cups. Total wear reported in these 40 components was not more than that reported in conventional cups with the same bearings [17].

Because of the presence of polyethylene, which is unavoidable in this type of component, we feel that its use should be limited in "young" patients. Thus it was only indicated as first-line treatment in relatively elderly patients (mean age: 76.6) in our series because we feel that this material should not be indicated as a first-line treatment in younger patients (less than 50). This is confirmed by Lecuire et al. [18] who described intra-prosthetic dislocations because wear of the rim of the polyethylene insert system resulted in escape of the metal head from the polyethylene which was then blocked in the metal cup. This type of dislocation seems to occur in the long-term in relatively young patients, while the risk seems to be rare after the age of 70 [19]. It could be due to mechanical fatigue, thus explaining the cumulative risk after many years. To prevent intra-prosthetic dislocation cup geometry has improved over the years. Thus at present most cups are cylindrical and spherical shaped with a notch at its inferior pole [20] between the anterior and posterior horn of the acetabulum. This shape limits the cam-effect on the inferior pole of the metallic cup while increasing superior covering. Moreover, the use of stems with polished, narrow necks are recommended to increase mobility and reduce impingement between the neck of the prosthesis and the polyethylene rim avoiding excessive friction wear. Thus the cup has no anterior and posterior overflowing edges to prevent possible impingement with the psoas [21], and between the femoral neck and the cup rim.

Orientation of the implants, in particular of the acetabular component can influence the incidence of dislocations [22]. In our study, we limited the influence of this factor by having all patients operated on by the same surgeon, with a similar positioning of implants. Although we did not perform any CT scan measurements of cup anteversion in the cases of dislocation, the radiological results of the position of the implants were satisfactory in all these cases.

Our comparison of THA with conventional (single mobility) and dual mobility cups in two comparable populations of older subjects at risk of instability, operated on by the same surgeon, limiting the confounding factors and risk of

bias, showed the advantages of a dual mobility cup showing the absence of postoperative dislocations in this population. Moreover, based on existing knowledge and our results, there was no additional morbidity with this type of implant.

Conflict of interest statement

None.

References

- [1] Hutten D, Langlais F. Luxations et subluxations des prothèses totales de hanches. In: Duparc J, editor. Cahiers d'enseignements de la Sofcot n° 90. Paris: Elsevier; 2005. p. 370–417.
- [2] Letournel E. Lagrange-Letournel hip prosthesis: results of 1355 cases. Proceedings of third Open Scientific Meeting of the Hip Society. Saint-Louis: CV Mosby; 1975. p. 278–99.
- [3] Vicar AJ, Coleman CR. A comparison of the antero-lateral, transtrochanteric and posterior surgical approaches in primary total hip arthroplasty. *Clin Orthop* 1984;188:152–9.
- [4] Phillips CB, Barrett JA, Losina E, et al. Incidence rates of dislocation, pulmonary embolisms and deep infection during the first six months after elective total hip replacement. *J Bone Joint Surg Am* 2003;85:20–6.
- [5] Hedlundh U, Ahnfelt L, Fredin H. Incidence of dislocation after total hip arthroplasty. Comparison of different registration methods in 408 cases. *Acta Orthop Scand* 1992;63:403–6.
- [6] Callaghan JJ, Heithoff BE, Goetz DD, Sullivan PM, Pedersen DR, Johnston RC. Prevention of dislocation after hip arthroplasty: lessons from long-term follow-up. *Clin Orthop* 2001;393:157–62.
- [7] Von Knoch M, Berry DJ, Harmsen WS, Morrey BF. Late dislocation after total hip arthroplasty. *J Bone Joint Surg Am* 2002;84:1949–53.
- [8] McKee GK, Watson-Farrar J. Replacement of arthritic hips by the McKee-Farrar prosthesis. *J Bone Joint Surg Br* 1966;48:245–59.
- [9] Charnley J. The long-term results of low-friction arthroplasty of the hip performed as a primary intervention. *J Bone Joint Surg Br* 1972;54:61–76.
- [10] Owens WD, Felts JA, Spitznagel EL. ASA physical status classifications: a study of consistency of ratings. *J Anesth* 1978;49:239–43.
- [11] Lecerf G, Fessy MH, Philippot R, et al. Femoral offset: anatomical concept, definition, assessment, implications for preoperative templating and hip arthroplasty. *Orthop Traumatol Surg Res* 2009;95:248–57.
- [12] Lautridou C, Lebel B, Burdin G, Vielpeau C. Survival of the cementless Bousquet dual mobility cup: minimum 15-year follow-up of 437 total hip arthroplasties. *Rev Chir Orthop* 2008;94:731–9.
- [13] Philippot R, Farizon F, Camilleri JP, et al. Survival of dual mobility socket with a mean 17 years follow-up. *Rev Chir Orthop* 2008;94:43–8.
- [14] Berry DJ, Knogh M, Schlek CD, Harmsen WS. Effect of femoral head diameter and operative approach on risk of dislocation after primary total hip arthroplasty. *J Bone Joint Surg Am* 2005;87:2456–63.
- [15] Aubriot JH, Lesimple P, Leclercq S. Étude du cotyle non scellé de Bousquet dans cent prothèses totales de hanche hybrides. Recul moyen de 5 ans. *Acta Orthop Belg* 1993;59(Suppl. 1):261–71.
- [16] Farizon F, Delavison R, Azoulai JJ, Bousquet G. Results with a cementless alumina coated cup with dual mobility. *Int Orthop* 1998;22:219–24.

- [17] Adam P, Farizon F, Fessy MH. Dual articulation retentive acetabular liners and wear: surface analysis of 40 retrieved polyethylene implants. *Rev Chir Orthop* 2005;91:627–36.
- [18] Lecuire F, Benareau I, Rubini J, Basso M. Intra-prosthetic dislocation of the Bousquet dual mobility socket. *Rev Chir Orthop* 2004;90:249–55.
- [19] Adam P, Philippot R, Dargai F, Coumert S, Farizon F, Fessy MH. Double mobilité et luxation intra-prothétique. *Rev Chir Orthop* 2005;91(Suppl. 6):185.
- [20] Leclercq S. Les limites de la double mobilité : à partir d'une expérience de plus de 15 ans. *Rev Chir Orthop* 2004;90:486.
- [21] Bricteux S, Beguin L, Fessy MH. Iliopsoas impingement in 12 patients with a total hip arthroplasty. *Rev Chir Orthop* 2001;87:820–5.
- [22] Bierdermann R, Tonin A, Krismer M, Rachbauer F, Eibl G, Stöckl B. Reducing the risk of dislocation after total hip arthroplasty; the effect of orientation of the acetabular component. *J Bone Joint Surg Br* 2005;87:762–9.